

## SPECIES DIFFERENCES IN EXPERIMENTAL LUNG CANDIDIASIS

V. L. Belyanin and A. Kh. Kerimov

UDC 616.24-002.828-092.9-  
092:612.017.1

KEY WORDS: candidiasis; pneumonia; phagocytosis.

As an infectious disease [14] arising not infrequently under conditions of secondary immunodeficiency, candidiasis has recently become a particularly urgent problem as a result of the increased frequency of its appearance [7]. The lung lesions which at times develop in the course of candidiasis are numbered among the threatening manifestations of the disease [10] and call for comprehensive study. When attempting to produce experimental models of the pneumonic form of candidiasis, investigators have tried to obtain complete similarity with candidiasis of the lungs in man by reducing the resistance of the host [12, 13] or they have tried to retain the agent in the alveoli with the aid of adhesive substrates (trogacanth, gum arabic) [8], which must also have disturbed the mechanisms of defense in healthy laboratory animals.

The aim of this investigation was a morphological study of the role of some natural defensive (principally phagocytic) responses of the body to rid itself of the infectious agent during intrapulmonary infection of animals of various species, in which pulmonary candidiasis follows different courses, during intrapulmonary infection with *Candida albicans*.

### EXPERIMENTAL METHOD

Experiments were carried out on 13 rabbits weighing 1.5-2 kg, on 10 guinea pigs weighing 250-270 g, and on 72 albino mice weighing 10-12 g. *Candida albicans* strain No. 13 was used to infect the animals, and the rabbits also were infected with another strain of equal virulence, isolated from patients (No. 643-Ch). To standardize infection of the rabbits, the method of injecting the culture into the trachea through a tube introduced into its cervical portion, in a dose of  $80 \cdot 10^6$  *Candida* cells in 0.5 ml of sodium chloride solution, suggested by A. Kh. Kerimov, was used. Standard results were obtained by intranasal infection of guinea pigs and mice under superficial ether anesthesia in a dose of  $125 \cdot 10^6$  *Candida* blastospores per animal. The rabbits were killed by air embolism between 6 h and 159 days after infection, the guinea pigs and mice were killed with ether from 10 min to 10 days after infection. The lungs were subjected to mycological investigation. Sections of the internal organs were stained with hematoxylin and eosin, by Goldman's and Van Gieson's methods, and, to detect the microflora and molds, the PAS reaction was carried out on sections stained with azure-eosin.

### EXPERIMENTAL RESULTS

Pulmonary candidiasis in rabbits was not fatal. After infection the animals became lethargic and most sounds appeared in their lungs. Pneumonic foci were discovered roentgenologically and macroscopically in the lungs, and in the late stages bronchiectasis frequently appeared (Fig. 1a). The inflammatory exudate consisted both of polymorphonuclear leukocytes (polymorphs) and of macrophages (Mph), actively phagocytosing the *Candida* cells, some of which actually formed short threads of pseudomycelium (Fig. 1b). By the 2nd day cells of Mph type containing PAS-positive masses predominated in the foci of inflammation, and most polymorphs were destroyed (Fig. 1c). *Candida* cells were few in number and were mainly only weakly PAS-positive, evidence of their death [6]. Many bronchi were surrounded by infiltrating lymphocytes and plasma cells. Their lumen was dilated and filled with detritus. On the 5th-13th day foci of cells similar to epithelioid cells also appeared in the lungs. In two rabbits, killed on the 53rd and 59th days, besides growth of connective tissue, numerous bronchiectases were present in the lungs, with abscesses of varied duration, whose cavities contained, among

---

Department of Pathological Anatomy and Department of Deep Mycoses, S. M. Kirov Postgraduate Medical Institute, Leningrad. (Presented by Academician of the Academy of Medical Sciences of the USSR D. S. Sarkisov.) Translated from *Byulleten' Eksperimental'noi Biologii i Meditsiny*, Vol. 103, No. 2, pp. 224-226, February, 1987. Original article submitted March 4, 1986.

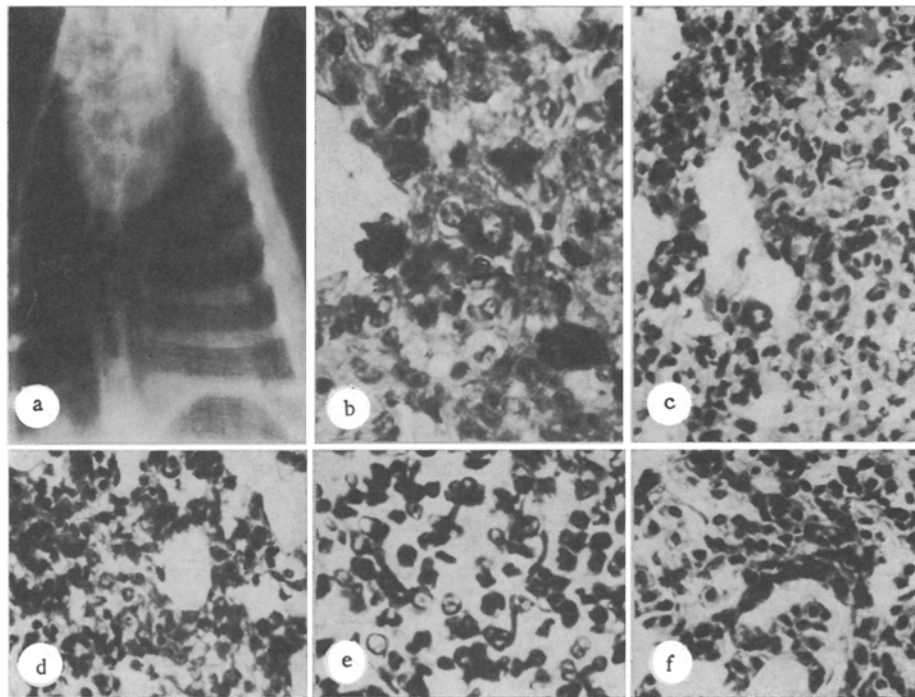


Fig. 1. Lung lesions due to *Candida albicans*. a) Roentgenogram of rabbit lungs 59 days after infection with *C. albicans*. No particular features found on right, regions of shadowing on left due to left-sided chronic pneumonia. b) *C. albicans* inside macrophages and leukocytes of exudate, filling lung alveoli, 6 h after infection of rabbit. 700 $\times$ . c) Predominance of macrophages in exudate. Two days after infection of rabbit. Azure-eosin. 400 $\times$ ; d) many leukocytes and macrophages present in exudate filling alveoli. Two days after infection of guinea pig. Hematoxylin and eosin. 400 $\times$ ; e) mainly polymorphs, phagocytosing *Candida* cells present in exudate. PAS reaction, hematoxylin. 700 $\times$ ; f) focus of cells of epithelioid type. Ten days after infection of a mouse. Azure-eosin. 400 $\times$ .

the detritus, microcolonies of a predominantly coccal flora. Compared with the pneumonic process in rabbits, foci of inflammation in the guinea pigs' lungs consisted of Mph with a considerable admixture of polymorphs (Fig. 1d). *Candida* blastospores were phagocytosed both by Mph and by polymorphs. Pseudomycelium formation by the *Candida* cells was observed extremely rarely.

After infection the albino mice were apathetic, and about 25% of the animals died in the course of 1 or 2 days. Animals which survived became active, and after the 4th-5th day after infection they appeared outwardly to be healthy; this correlated with the decrease in the number of positive seedings of the mold by this time to  $6.6 \cdot 10^2$  and by their disappearance from the lungs by the 10th day. Foci of inflammation consisted chiefly of polymorphs, actively phagocytosing the *Candida* cells (Fig. 1e), and destroyed, which also caused death of the mold (nonphagocytic types of resistance [5]). Considerable destruction of polymorphs, combined with marked hemorrhagic edema of the lungs, was observed in some mice toward 15-18 h after infection. Death of the animals, probably from hypoxia, began at these same times. In foci of inflammation there were few Mph on the 1st-3rd day, and they carried out very little phagocytosis of the *Candida* blastospores. By the 7th day no *Candida* cells could be found in the lungs, and foci of cells of Mph and epithelioid type were found in the tissues (Fig. 1f). Around the vessels and dilated bronchi, in both rabbits and guinea pigs, dense areas of infiltration by lymphocytes and plasma cells were present.

The intratracheal method of infection of rabbits and intranasal infection of young mice and guinea pigs thus enabled pneumonia due to *Candida albicans* to be produced in laboratory animals without the use of adhesive substances, such as were used by other workers [8], and

the disease followed a less severe course in rabbits and a more severe course in albino mice. In guinea pigs the character of the course of the process and its morphological manifestations occupied an intermediate position. Although this model is not an analog of candidiasis of the lungs in man [9, 10], it is suitable for the study of the pathomorphogenesis of that disease, for according to Voino-Yasenetskii [2], it is perfectly suitable to use for this purpose models of its separate stages, which for various reasons cannot be subjected to detailed analysis in man.

During morphological investigation of the process in the acute stage, the general principles governing the development of local protective reactions in the lungs of animals of all species in response to introduction of *C. albicans* were discovered and, in particular, the successive replacement (after about 24 h) of the leukocytic response by a macrophagal response. However, the macrophagal response was most marked in rabbits, while the leukocytic response was relatively moderate, without any abundant destruction of polymorphs. Macrophages and polymorphs successfully phagocytosed the mold, probably due to active biochemical systems not only of polymorphs, but also of Mph in rabbits [4, 11].

The particular features of the process in albino mice were a considerable leukocytic reaction with ingestion of the Candida cells by polymorphs, and the "nonphagocytic" type of resistance, manifested along with the phagocytic type, as reflected in mass destruction of polymorphs and, as a result of this, death of the mold. The macrophagal response in mice was weak. Nodules of cells similar to epithelioid, found as the outcome of acute inflammation in the lungs of all species of animals, evidently developed through the action of antigenic substances of the destroyed mold on the lung tissue [1, 8]. The infiltration of lymphocytes and plasma cells around the bronchi is evidence, probably, of active involvement of specific mechanisms of immune protection [3].

Comparison of the manifestations of inflammatory processes in the lungs of animals of different species showed that removal of all *C. albicans* cells from the host is effected mainly by polymorphs. At the same time, it can be postulated that active cooperation between the functions of all cells of the phagocytic system, both polymorphs and Mph, will lead to more effective clearance of the body from *C. albicans*.

The study of species differences in the course of candidiasis of the lungs can enable the mechanisms of the protective responses of the body in candidiasis to be characterized more completely.

#### LITERATURE CITED

1. V. L. Belyanin, R. A. Araviiskii, and A. V. Elias, *Arkh. Patol.*, No. 12, 20 (1984).
2. M. V. Voino-Yasenetskii, *The Biology and Pathology of Infectious Processes* [in Russian], Leningrad (1981).
3. G. Dick (editor), *Immunological Aspects of Infectious Diseases*, Lancaster (1979).
4. J. Carr, *The Macrophage, a Review of Ultrastructure and Function*, London (1973).
5. V. E. Pigarevskii, *Granular Leukocytes and Their Properties* [in Russian], Moscow (1978).
6. O. K. Khmel'nitskii, *Histological Diagnosis of Superficial and Deep Mycoses* [in Russian], Leningrad (1973).
7. O. K. Khmel'nitskii, R. A. Araviiskii, and O. N. Ekzemplyarov, *Candidiasis* [in Russian], Leningrad (1984).
8. A. V. Tsinzerling, *Candidiasis of the Lungs* [in Russian], Leningrad (1964).
9. G. Bader, *Die viszeralen Mykosen*, Jena (1965).
10. H. Gemeinhardt, *Endomykosen des Menschen*, Jena (1976).
11. E. Grogg and A.G.E. Pearse, *Brit. J. Exp. Pathol.*, 33, 567 (1952).
12. W. Masshoff and W. Adam, *Arch. Klin. Exp. Derm.* 204, 416 (1957).
13. F. de Potter, *C. R. Soc. Biol.*, 69, 425 (1923).
14. C. L. Taschdjian, P. J. Kozinn, and E. F. Toni, *Ann. New York Acad. Sci.*, 174, 606 (1970).